

# Dental implants: a different perspective

## Part one

Implant practice could involve no surgery, no special equipment, no stress and simple procedures, as well as being profitable, debates Mark Haswell, as he outlines what the future of implant dentistry might hold

### History

Dental implants have been utilised by mankind for thousands of years, but it is only recently that they have achieved widespread acceptance from the profession at large. This has resulted in extensive academic investigations and scientific testing. This was brought to the fore by the ground-breaking work of Professor Branemark and Andre Schroder. Implants have become more and more mainstream since the Toronto meeting in 1983 when Professor Branemark released his extensive research findings to specialist dentists.

Since that time there has been a rapid growth in the use of dental implants in all areas of the world.

We have now reached the point where, in many situations, dental implants are the first choice restorative tool for the replacement of a missing tooth or teeth. They provide predictable and aesthetic long-term solutions for an increasing number of patients around the world.

### Worldwide professional view of implants

Dental implants are used in many countries world-wide to facilitate dental rehabilitation. If one consults the research literature, one can find articles from dental schools and universities from nearly all countries around the world. This breadth of research on different designs of implants and manufacturers of implants has increased our knowledge base, not only about specific implants but also about different types of treatment. While dental implants are extensively used in all dental schools throughout the UK in both the postgraduate teaching programmes and by clinical staff, unfortunately there is no undergraduate training in the use of dental implants.

Currently in the UK there is no hands-on patient-based instruction in the use of dental implants from a surgical perspective, restorative

---

**Mark Haswell BDS MSc (implant dentistry) is a specialist in prosthodontics, with special interest in perio, implant restorative work and gerodontology.**

### Abstract

**Here is a different, practical and realistic world perspective of dental implants. The author takes an overview of the subject matter and evaluates whether dentists should be choosing to work with implants in general practice**

perspective or even treatment planning perspective for undergraduates. Undergraduates are exposed to the general theory behind the use of dental implants as an option for tooth replacement so that they are able to inform patients of their options, in order that the patients can give informed consent for the treatment of tooth loss.

Research has shown that if our dentists are exposed during their undergraduate training to both the use of dental implants and the restoration of them, they are more likely to offer this type of treatment and become involved in the restoration of their own patients with this treatment modality in the future<sup>1</sup>.

### Market development

The use of dental implants in the UK has lagged greatly behind that of all our European neighbours, as well as North America and many countries in South America and the Far East. This is really related to the number of dentists who are trained to utilise this type of treatment, which is approximately 10% of the total of 20,000 (ADI membership committee). As opposed to the USA, which has 82% trained in the utilisation of dental implants, and Italy where 95% of dentists are undertaking implant-based treatments. Some 78% of general practitioners in the US have restored fixed or removable prostheses utilising dental implants.

The use of dental implants is also limited by our historical dependence on the NHS system of payment for dental treatment. This has created an artificial barrier to the usage of dental implants, because dental implants are not funded for all but the most serious hypodontia cases, cancer or trauma within the NHS. The cost comparison between dental implants and bridgework within the NHS, if this is even of-

fered to the patient, would be difficult for the patient to understand, despite the attraction of no trauma to adjacent teeth.

### What is the future?

The number of dental implants placed in USA increased 10-fold between 1983 and 2002; there are now over 700,000 implants inserted annually. This is expected to increase at a sustained growth of 9.4% for the next several years.<sup>15</sup>

Currently in the UK the use of dental implants is about nine per 10,000 citizens (Straumann, 2005). This compares with five per 10,000 citizens in 2003.<sup>17</sup>

Diagram 1 shows the comparative usage of implants and illustrates the increase in the years between 2003 and 2005. The graph also shows the relative lack of usage and acceptance of this technology in the UK. This does not correlate with the demographic profile of our population, which shows more and younger edentulous and partially edentulous patients compared to our industrial trading partners. Neither does it fit with the position of our national wealth and per capita income in relation to those same countries. However, the following quote from the Commons Select Committee on Health may help to explain the slow market growth:

*'The scarcity of skills in the UK is associated with high prices. Cost quoted in the UK are typically £2,000 per implant upward compared with about £1,000 or less in some other European countries. Costs are widely expected to fall with the development of supporting technologies. But because of the scarcity of implantologists in the UK, falling costs can be expected to increase the difference between the high costs in the UK as compared with the low cost in other countries.'* (Thomas R, 2005)

## What is likely to happen?

As our population ages, patients will require and demand more dental care. But what type of care? There is, I believe, going to be an inevitable increase in implant-based dentistry.

This increased need and use of implant-related treatments result from the combined effect of a number of factors:

1. Ageing population living longer
2. Tooth loss related to age
3. Tooth loss as a consequence of the loss of fixed prostheses
4. Anatomic consequences of edentulism
5. Poor performance of removable prostheses
6. Consequence of removable partial dentures
7. Psychological aspects of tooth loss
8. The desire for a youthful appearance by the ageing baby boomers
9. Predictable long-term results of implant-supported prosthesis
10. Advantages of implant-supported prostheses.

The largest demographic group – the baby boomers – is moving into middle age and later middle age. These are patients born between 1946 and 1964. This group of patients also have the most restored teeth in history. They have been instrumental in developing a youth orientated culture and they now have a desire to maintain youth. This is evident from the rapid expansion of makeover shows (for example *Ten Years Younger* and *Extreme Makeover*). These shows are exposing a knowledge-hungry population open to the advances in aesthetic medicine and dental technology.

This group of patients have been predicted to drive the usage of dental implants in industrialised countries. The market trend predicts a 15% annual growth between 2002 and 2010 across the whole of Europe (Nobel, 2006). This study also predicted stronger growth in the UK due to the then very low usage and market penetration. This same study estimated that in the UK 3.8m people older than 55 may be edentulous in one jaw, compared to 200,000 in Sweden. Sweden has been utilising dental implants since 1965 in the general population (currently fully edentulous patients still receive state-funded dental implant treatment). The position in the UK is obviously a considerable mismatch relative to other population indicators. It therefore seems certain that the UK dental profession will be called on to provide patients with more dental implant treatment.

## Patient satisfaction with dental implants

A review of patient satisfaction<sup>2</sup>, as opposed to the normal scientific study of clinical outcome, revealed that patients viewed their experience

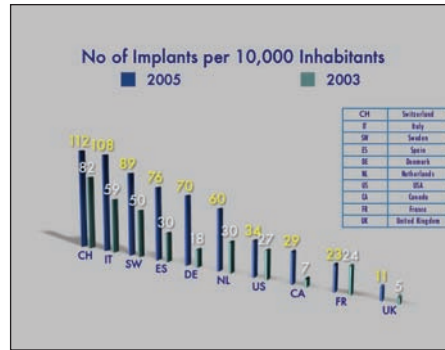


Diagram 1

with dental implant-based restorations in a very positive light. They felt they had received improved function and greater confidence with their dental appearance. The cost of the procedures was also not viewed as a negative when weighted against their functional or aesthetic gains.

The dental profession now needs to see that we have an excess of patient demand, for a product of which not all the population is presently aware. This product or solution is viewed as beneficial by the patient. Allied to this, implant-based restorations have also been shown to be clinically predictable and provide many advantages over conventional alternatives.

Consider the common clinical occurrence of a failed central incisor. Would a fixed bridge provide a comparable solution to the replacement with an implant supported crown? Our patients must be informed of the alternative treatment options for its replacement, such as:

- Maintenance of the gap
- Use of a removable denture
- Use of a bridge, either conventional or adhesive
- Use of an implant-supported crown.

In such a young patient (aged 36) (see Figures 1, 2 and 3) the alternatives have significant drawbacks, with potential for functional and aesthetic failures<sup>3</sup> due to:

- Caries – around retainers or wings
- Bone loss under pontic
- Periodontal disease associated with a denture
- Endodontic lesion due to loss of vitality under a fixed retainer.

Alternatively, the use of dental implants will maintain the alveolar bone and the integrity of the adjacent teeth.<sup>4</sup>

These factors, together with the proven financial benefit<sup>5</sup>, will add up to a very significant increase in the demand for dental implant-based restorations. This cost benefit may seem strange since implant-based treatment is perceived as expensive. However, this Swiss

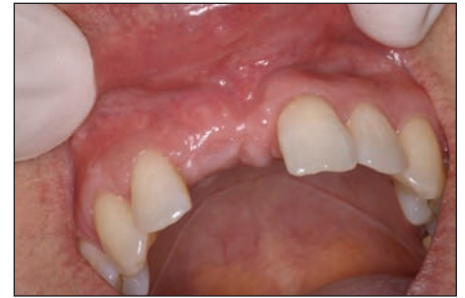

Figure 1: Missing tooth in spaced anterior segment

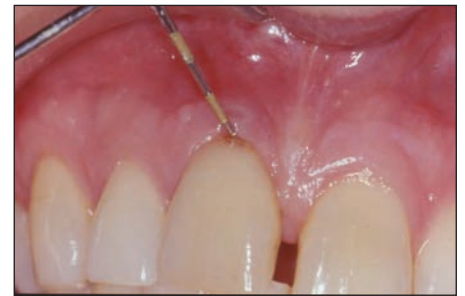

Figure 2: Failing incisor

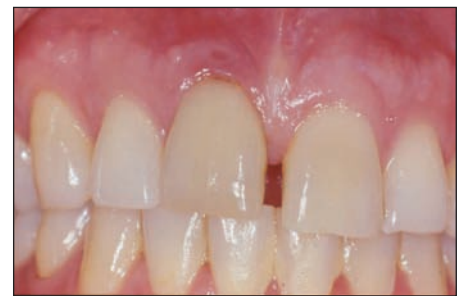

Figure 3: Missing tooth in spaced anterior segment

study showed the cost effectiveness of the use of a single implant when compared to a three-unit bridge.

This finding gives further weight to the already impressive clinical benefits that implant-

**'Conventional single-tooth replacement with fixed partial dentures (FPDs) exposes the abutment teeth as well as the reconstruction to several biological and technical risks such as endodontic complications, secondary caries, difficult access for plaque control resulting in periodontal complications, loss of retention fractures of teeth and/or the FPD. A single crown on an implant might therefore be the treatment of choice, even if the patients have to undergo a surgical intervention.'**<sup>5</sup>

*'Over a short observation period, implant reconstruction demonstrated a more favourable cost/effectiveness ratio for single-tooth replacement compared with conventional FPD. Especially in situations with either non- or minimally restored teeth and sufficient bone, the implant reconstruction is to be recommended from an economical point of view.'*<sup>5</sup>

*'This finding gives further weight to the already impressive clinical benefits that implant based replacement has when compared to conventional alternatives.'*<sup>13,14</sup>

based replacement has when compared to conventional alternatives.<sup>13,14</sup>

## Where will the patients be able to get implant-based restorations?

Currently there are thought to be approximately 2,000 dentists providing some aspect of implant dentistry (Association of Dental Implantology – based on industry estimates). Some practices provide a significant number of treatments per year, while others provide a few restorations over the same period. Some will work in a team system with one practitioner placing the implants and others restoring. Others will provide all aspects of implant treatment to their patients and/or those referred to them.

*'There are many things the NHS can do to raise knowledge and skills of implantology among its own staff. But there is no obvious way of bringing a whole generation of dentists in the UK up to a standard that seems common in other European countries.'*<sup>26</sup>

Unfortunately, with minimal training at undergraduate level, dentists must gain their education and experience after qualification. However, until recently no prescriptive approach to this education had been produced. There was no barrier to dentists starting implant practice, other than the General Dental

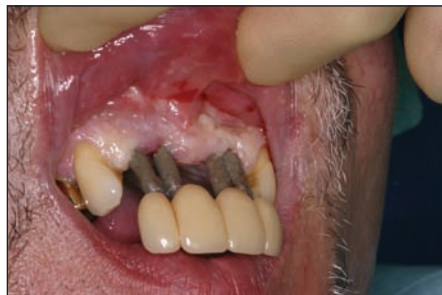

Figure 4: Failed four-unit implant bridge

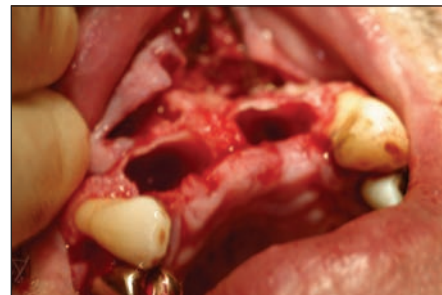

Figure 5: Bone defect caused by failed bridge

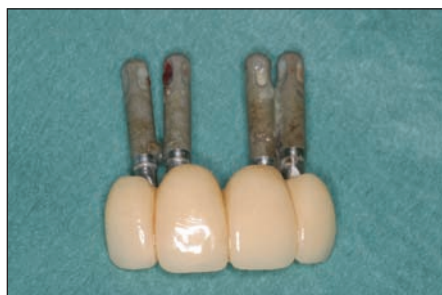

Figure 6: Explanted implant bridge

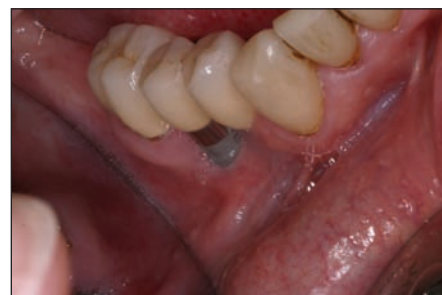

Figure 7: Exposed implant

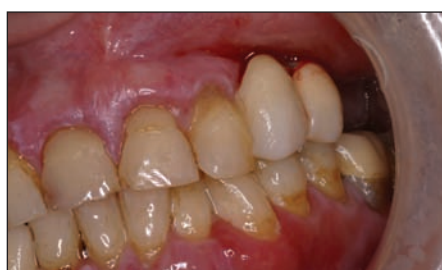

Figure 8: Bridge on malaligned implant

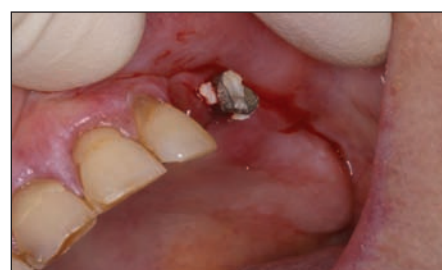

Figure 9: Abutment of malaligned implant

Council (GDC) stipulation that dentists should be able to show competence and knowledge. Recently guidelines have been produced by a working group set up in 2005 under the direction of the GDC. The remit of the independent working group was to consider which training standards would be necessary for a general dental practitioner to have achieved before practising implant dentistry. These are now published and will be reviewed periodically in light of published research.

*Training Standards for Implant Dentistry 2005* has to be applauded, as it will give patients confidence and ultimately a better service, and help to maintain the good outcome of implant restorations. It will also help to avoid problems such as those shown in Figures 4 to 9.

The number of course places for recommended implant education equate to no more than 300 places per year within the UK, with the number available for more advanced courses providing education on all aspects of implant treatment being less than 100 per year.

This limited number of training opportu-

nities also highlights another problem which is the cost (or investment) in education. This must also be added to the costs of equipment and stock necessary for the implant practice. These are essential long-term investments. To this must be added the cost of gaining experience. This is usually equated to approximately 50 cases under supervision to achieve competence<sup>6</sup>.

The acquisition of experience is likely to be allied to a mentoring programme recommended and ultimately mandatory. This additional level of training or 'on the job guidance' is likely to be invaluable in avoiding pitfalls and litigation. It will also slow the growth in qualified practitioners, as well as increasing the costs of the education path.

However, it should be possible for dentists to offer implant dentistry to their patients without years of training and without investing tens of thousands of pounds.

The wider adoption of a referral culture will allow the general practitioner to be as involved as they would like to be in the treatment of

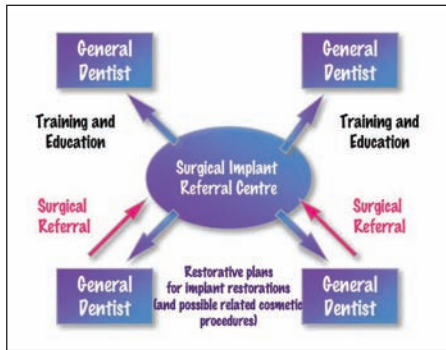


Diagram 2

their patients using implant dentistry (Diagram 2, above).

## Practitioner opportunities

1. Educating patients about options
2. Preparatory treatment
3. Tissue preservation
4. Restoration of implants.

All the GDP requires is a working relationship with a surgical implant centre, knowledge of the restorative principles of at least one implant system, the 'tool kit' for that system, and a detailed working knowledge of:

- Occlusion
- Implant occlusion
- Periodontal and implant maintenance.

In the USA the majority of general practitioners restore implants<sup>1</sup>. This should provide a model for the UK, allowing the creation of a hub and spoke system or GDP and surgical networks.

## Why should a busy GDP be bothered?

1. It will awaken an interest in a developing and growing area of dentistry
2. Creates a positive view of one's own practice, which will be viewed as offering contemporary solutions
3. The potential to enhance the patient/dentist relationship. The dentist is recommending all available solutions, some of which he is perceived to have little or no financial interest in
4. The chance to internalise as many stages of treatment as desired within one's own practice

This will:

1. Enhance and maintain the dentist/patient relationship
2. Enhance practice profitability
3. Develop a maintenance programme that will also act as profit centre
4. Enhance patient's dental awareness and knowledge
5. Create a positive view of the practice as high tech in patients' minds and, potentially, the minds of their friends/families.

The network of surgical implant centres and trained GDPs offering implant dentistry, should help practitioners to overcome the main barriers to starting implant-based treatment, namely a lack of education and fear of litigation<sup>7</sup>.

## Discussing options

The discussion of options for a patient's treatment should be related to the clinical situation of each and every patient. How a patient will view these varying options for the replacement of one or more teeth depends on their perspective in relationship to dental treatment.

Patients will have different agendas relating to prospective tooth loss or replacement depending on previous experiences, self-image, profession, life expectancy etc. These may be discussed in the following terms:

1. Will it hurt?
2. Will it look natural?
3. How long will it last?
4. How much will it cost?
5. How well will it function?

These various factors related to each and every patient will vary in importance depending on the patient's personality and expectations. No two patients will respond in the same way to the potential loss of a tooth. The replacement of the tooth or teeth can be treated in many and varying ways. A patient should, however, be offered all clinically viable solutions. These would in general be:

- No treatment
- Replacement with a removable denture
- Replacement with adhesive bridgework
- Replacement with conventional bridgework
- Implant replacement.

The duty of each and every dentist will be to offer the patients a full spectrum of replacement solutions. A dental practitioner will not be able to hide behind the statement that they do not offer that 'type of treatment', if asked to justify a potential treatment plan or treatment that has been carried out for replacement of a tooth.

As the information age gathers pace the facts are widely available, although not always interpreted in a correct fashion. However, our patients are aware of many and varied options, and are increasingly utilising the media and the internet to gain their information. It would seem ideal that the dental profession take this opportunity to inform their patients of all potential options, and the pros and cons of these choices, thereby enhancing the professional relationship.

For many patients, the potential replacement of the failing tooth or teeth with a man made tooth replacement that causes no damage

to adjacent teeth, prevents the potential for jaw bone shrinkage and provides nearly comparable function to the previously lost tooth is the ideal<sup>5,2,13</sup>. When we look at the usage of implants in other developed economies it seems absurd that so few implants are used within our population compared to the countries such as Sweden and Switzerland (Diagram 1, page 43). If this is the case, one must ask why so few implants are used in this country compared to these others. The likely conclusion is that the dental population as a whole has been poorly educated and advised as to the potential treatments, and that there are few amongst our dental profession who are able to offer this treatment<sup>7</sup>. It could also be that UK patients are less motivated compared to their continental and American counterparts. However, this seems likely to be an historical fact, at best, considering the rise of cosmetic surgery and an image based society.

*'A perfect smile is rapidly becoming the American icon, the hallmark of an affluent society.'* (I Mandel, JADA 1998)

*'Increasingly patients are seeking out cosmetic treatment with continued growth in the private dentistry market.'* (OFT Consumer report)

*It is easy to be mean about British teeth. Mike Myers's mouth is a joke in itself in the 'Austin Powers' movies. In a 'Simpsons' episode, dental-phobic children are shown 'The Big Book of British Smiles,' cautionary photographs of hideously snaggletoothed Britons. In Mexico, protruding, discolored and generally unfortunate teeth are known as 'dientes de ingles.'* (The New York Times, May 2006)

So comments like these may become a thing of the past as consumer demand increases.

If your patient showed an interest in implant dentistry and asked to proceed with implant therapy, historically the options were to:

1. To have a go
2. Refer to an implant centre.

As I have stated above, the potential for 'having a go' without adequate training is something that cannot be countenanced. The potential for referring a patient for implant therapy should and has been considered the norm in the recent past and it is up to the practitioner when referring patients out to ensure that the practice and individual to whom they are referring has adequate skills. This is due to the stipulation that the General Dental Council makes about potential referrals and the duty of care that the general practitioner has. In most situations the referral practice has, by and large, acted as a centre for the completion of the replacement tooth or teeth, which has involved:

1. Treatment planning and case discussion

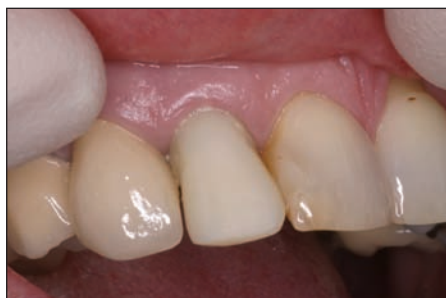

Figure 10: Immediately loaded temporary crown after 10 weeks of bone and soft tissue healing

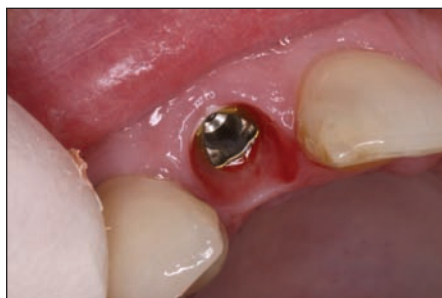


Figure 11: Head of Replace select implant showing healthy gingival arch

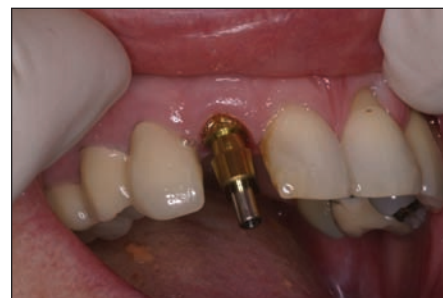

Figure 12: Fixture head impression coping in place, ready for open tray impression

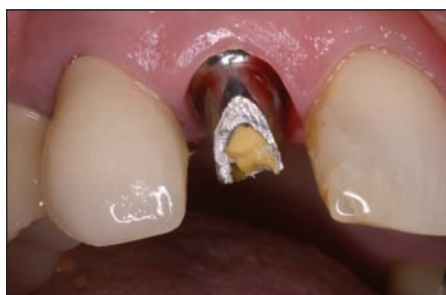

Figure 13: Permanent abutment in situ

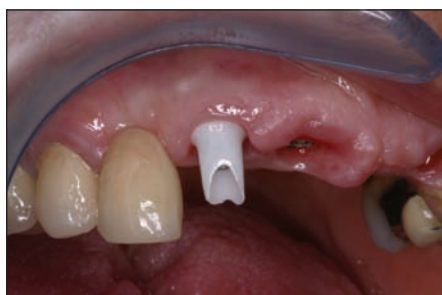

Figure 14: Similar case with zirconia abutment in place

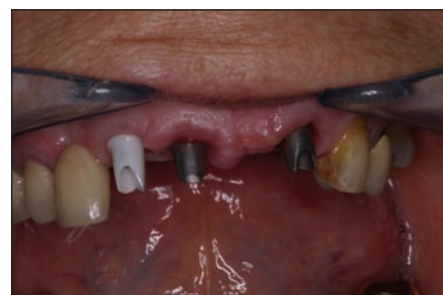

Figure 15: Placement of zirconia and sand-blasted titanium abutments

2. The preparation and placement of implants and any associated provisional treatment
3. The restoration of that tooth
4. The re-referral back to the practice for maintenance (Figures 10 to 16).

However, there is a huge potential for general practitioners to work in a team structure with implant referral centres<sup>1</sup>. A recently published survey of dental practitioners showed that only a tiny fraction (2.8%) were placing or restoring implants, but 35.9% wished to be involved with implants in the future<sup>7</sup>.

## How might this relationship work?

There are three potential levels of involvement that we have instituted within our referral centre.

- **Level one:** involves the referral of the patient for all stages of treatment, including diagnosis, provisional restoration, implant placement and restoration

- **Level two:** involves the treatment of the patient as a team. Within this structure the referring practitioner would provide provisional solutions under the direction of the implant centre. The implant centre would then provide the patient with the surgical aspects of treatment, possibly involving bone augmentation should this be required. The referring practitioner would then be able to restore the final restoration using either:

### Option A

The fitting of an abutment by the referring

practitioner and then making an impression of the implant abutment back at the general practice (Figures 17 to 23) followed by the cementation of the final restoration, or:

### Option B

Taking conventional fixture head impressions of the implant (see Figures 10 to 16 and 24 to 64) (i.e. the top of the implant). This will then allow the trained technician to make or refine an implant abutment (post) and construct a crown or restoration. Both of these elements will then be fitted by the referring dentist.

- **Level three:** this would be co-diagnostic treatment, whereby the referring practitioner provides an outline plan for the implant restoration together with the final restorative solution. Within this level of team treatment the referring practitioner would be able to undertake all preparatory treatment, potential tissue preservation following extraction of teeth and, ultimately, the restoration of the implant using either abutment level impressions or implant level impressions.

It is my hope that more practitioners will start to work in this network style. This will

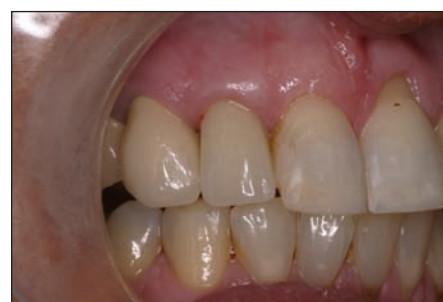

Figure 16: Final bonded crown restoration in place

create a greater capacity for patients to be treated by skilled and trained 'implantologists' in conjunction with appropriately educated general practitioners. This will allow more patients access to the treatment, which will, in turn, spread the good news about implant-based dentistry and how it can help our patients.

As a general practitioner, potentially at least 50% of the treatment can be carried out within your practice.

## Tissue preservation

What is meant by tissue preservation? All dentists will recognise the inevitable consequence of extractions: the shrinkage of the alveolar

General practice	Implant dentists (implantologists)
1) Diagnosis of impending tooth loss	1) Treatment plan
2) Tissue preservation and extraction	2) Implant placement and bone grafting
3) Provisionalisation, restoration	
4) Permanent restoration	

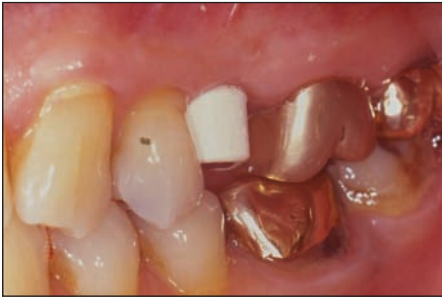

Figure 17: Healing cap over Easy abutment

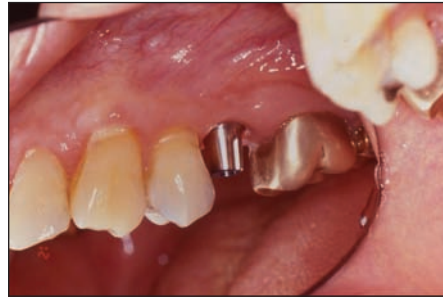

Figure 18: Lateral view of Easy abutment in situ




Figure 19: Snap-on impression coping

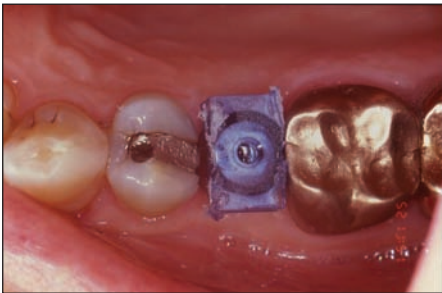


Figure 20: Snap-on coping (trimmed), ready for impression

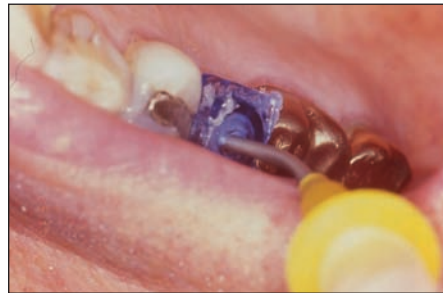

Figure 21: Impression technique using special centrix mixing tip and light and heavy body impression material

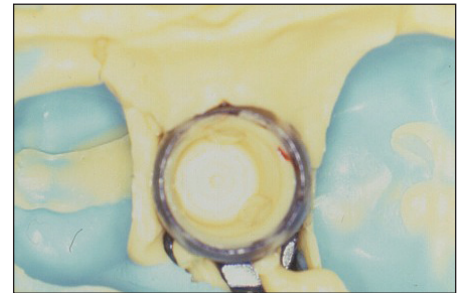


Figure 22: Impression of snap-on

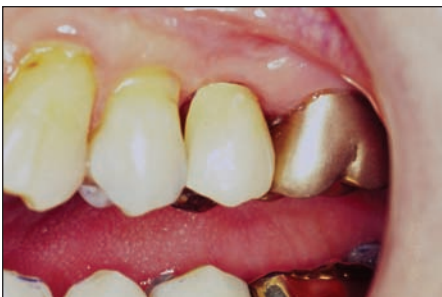

Figure 23: Final crown in situ. Lateral view

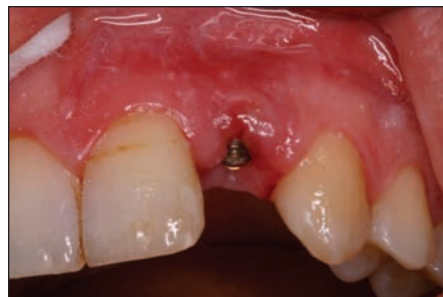

Figure 24: Healing abutments in situ

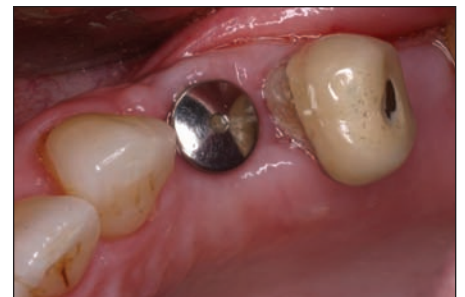

Figure 25: Ankylosis healing abutment in situ

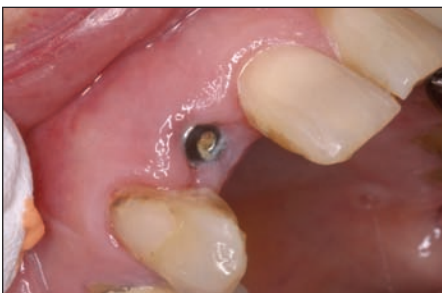


Figure 26: Healing abutments in situ



Figure 27: Torque wrench and screwdriver

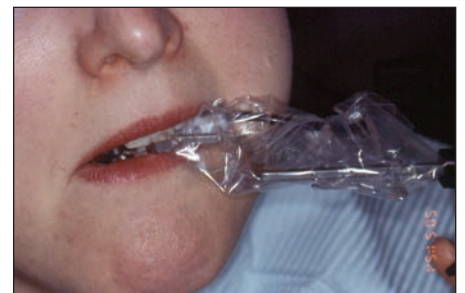
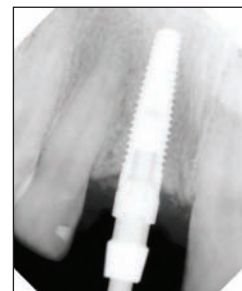
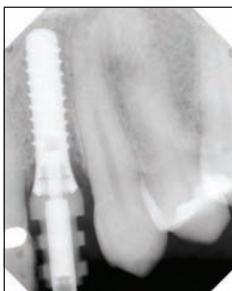Figure 28: Check X-ray to ensure accurate seating of components to give a record of implant bone levels



Figures 29, 30 and 31: X-rays showing healthy bone level

# Clinical debate

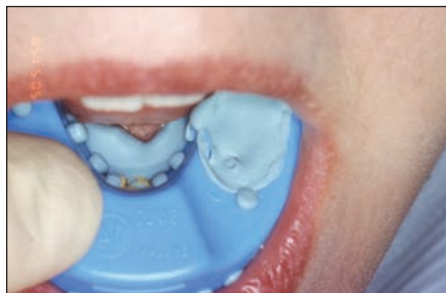

Figure 32: Open tray impression with screw hole visible

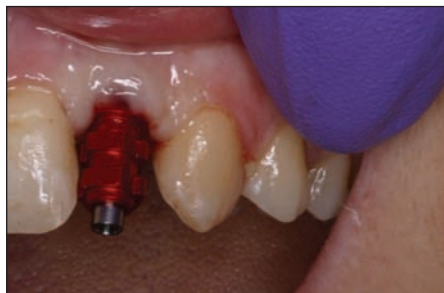

Figure 33: Fixture head impression Of Straumann implant

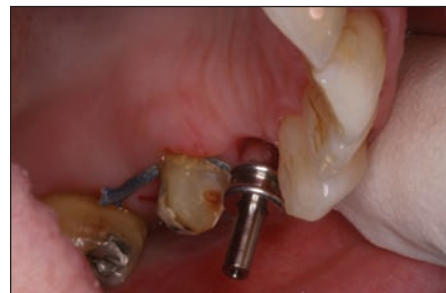

Figure 34: Open tray impression coping in situ

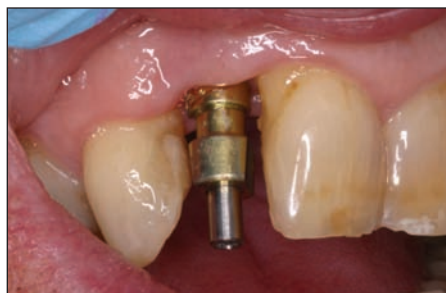

Figure 35: Nobel Replace

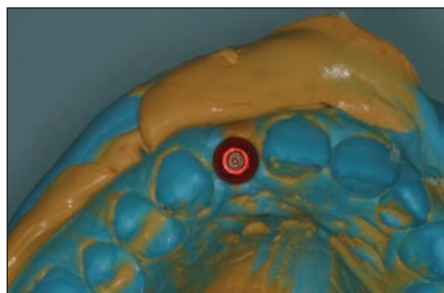


Figure 36: Impression of Straumann implant




Figure 37: Successful impression of tooth and implant



Figure 38: Completed impressions

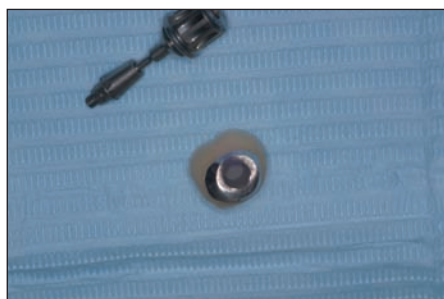


Figure 39:

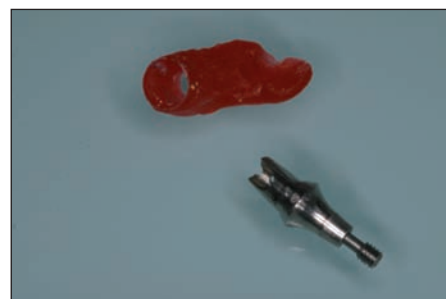

Figure 40: Abutment and fitting jig

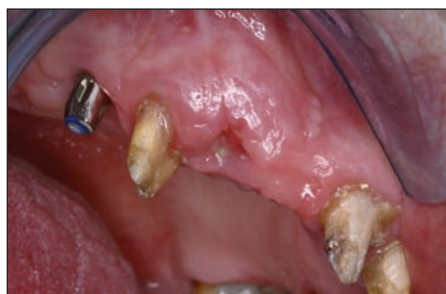

Figure 41: Ridge contour four months later

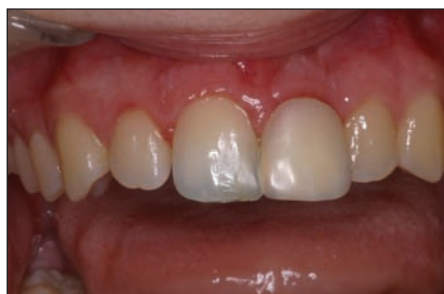

Figure 42: Tooth 11 seven years after extraction and socket preservation

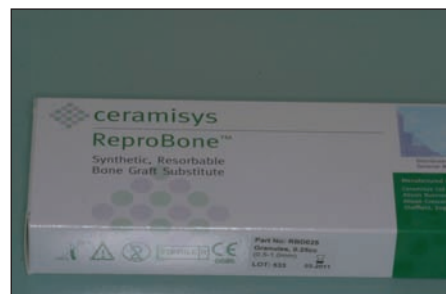


Figure 43: Reprobone synthetic Allograft

bone in a horizontal and vertical dimension. This ultimately makes achieving aesthetic dental restoration very difficult, be they implant supported or conventional dentures or bridges.

Lekovic<sup>8</sup> and Tallgren<sup>9</sup> have shown that after tooth extraction the socket will shrink horizontally by 3-4mm over the first 12 weeks. There is also a more gradual vertical shrinkage. If the extraction is traumatic (difficult), greater

bone loss can be expected.

This loss of bone will create problems for the implant surgeon when planning and executing implant placement. It will also hinder the dentist if using conventional restorative techniques and, ultimately, will end in disappointment for the patient.

If the patient presents with tissue loss but still requires implant surgery, various techniques are available to rebuild the lost bone:

- Guided Bone Regeneration (GBR): the use of a membrane shield to protect and retain a bone grafting material to rebuild the alveolar ridge profile (Figures 58, 59, 60)
- Alveolar block grafting: this involves the transplanting of mandibular bone from a donor site to the resorbed area. The donor bone is then secured into position and allowed to heal into position. Once successfully healed implants can be placed into the bone



Figure 44: Titanium abutment and crown

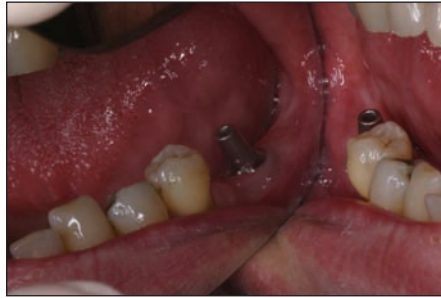

Figure 45: Straumann abutment connected to wide neck implant

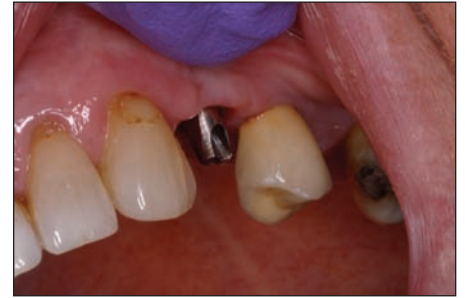

Figure 46: Abutments in position

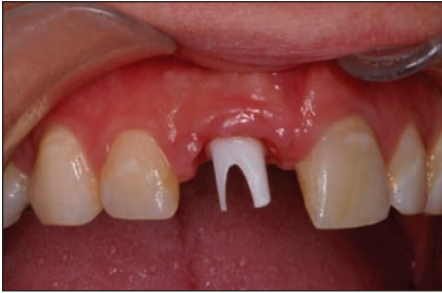

Figure 47: Abutments in position

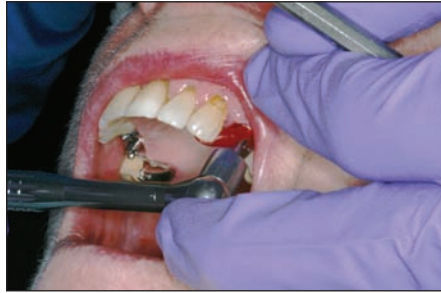

Figure 48: Abutments torqued into position – locating the jig in position

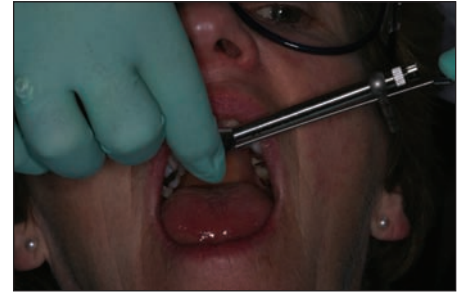

Figure 49: Abutments torqued into position – locating the jig in position

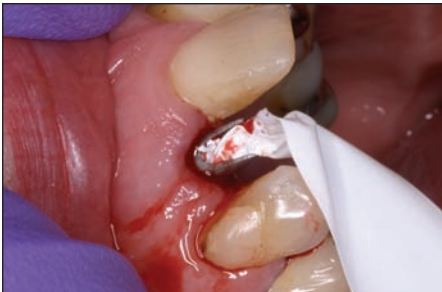

Figure 50: Filling of the screw access hole with PTFE tape

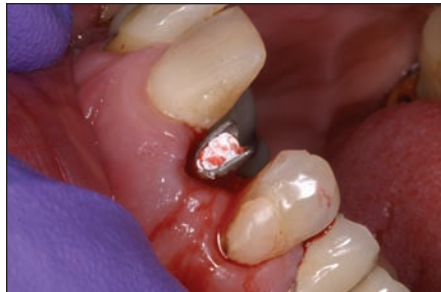

Figure 51: Obturated screw access hole

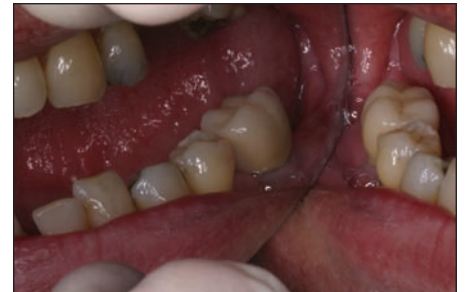

Figure 52: Crown restoration cemented into position

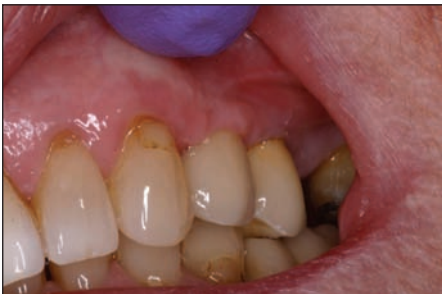

Figure 53: Final restoration in place

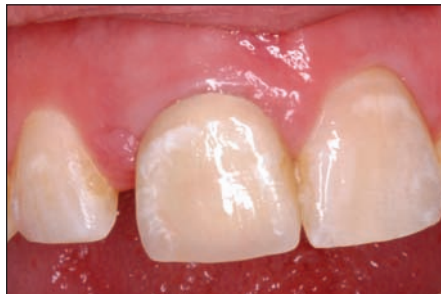

Figure 54: Final restoration in place

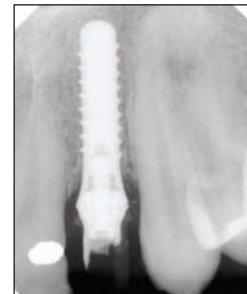

Figure 55: Post fit check X-ray

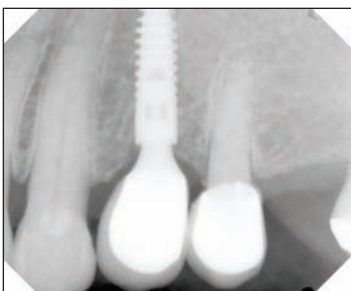


Figure 56: Post fit check X-ray

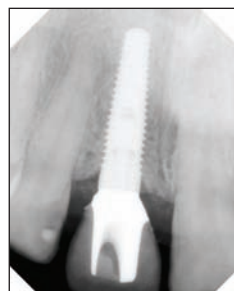

Figure 57: Post fit check X-ray

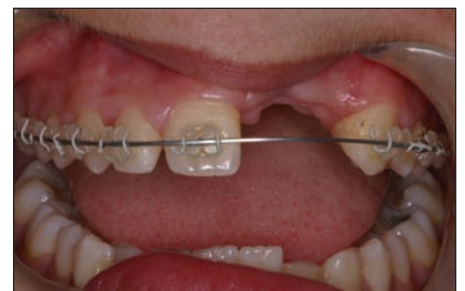

Figure 58: Ridge defect after extractions with no socket preservation undertaken



# Clinical debate

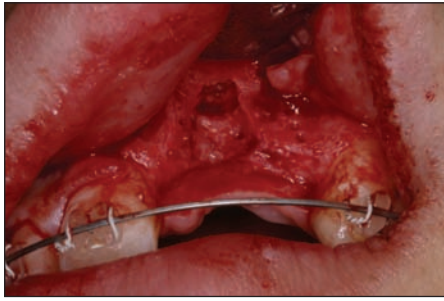

Figure 59: Ridge defect

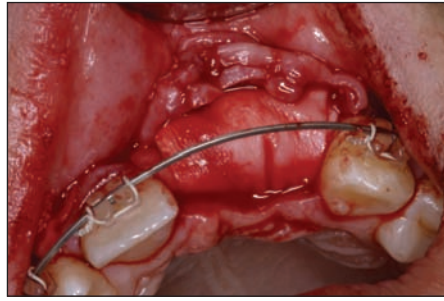


Figure 60: Guided bone regeneration with Bio-Guide and Bio-Oss (Geistlich)

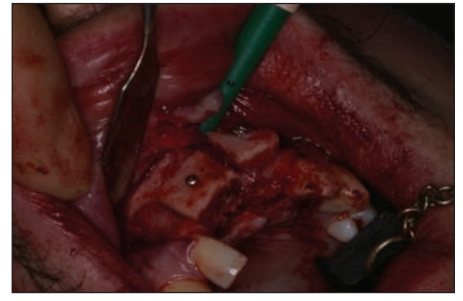

Figure 61: Alveolar block grafting to repair lost buccal plate after motorcycle accident

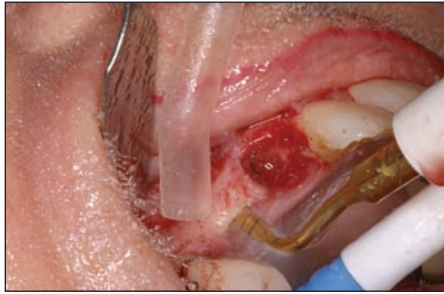

Figure 62: Piezo surgery cut for ridge splitting

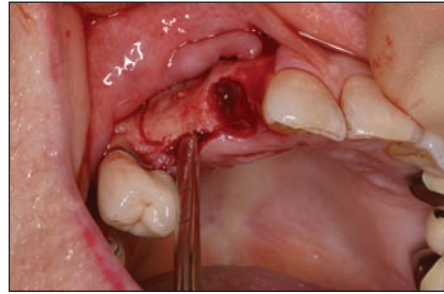


Figure 63: Splitting of alveolus to allow implant placement at the same time and bone augmentation

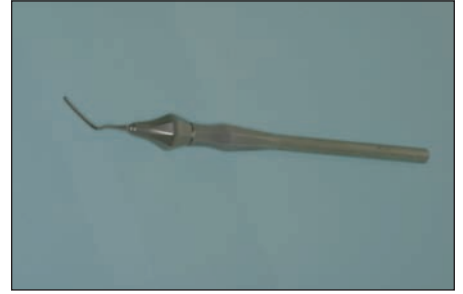

Figure 64: Periosteum



Figure 65: Luxator set (Dentsply Ash)

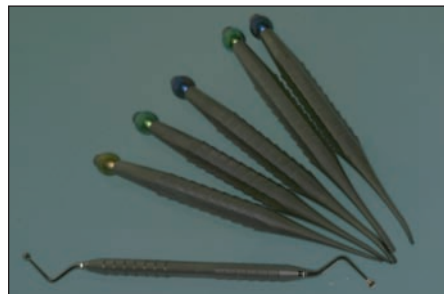

Figure 66: Luxator set (General Medical) with curette to clean soft tissue from socket



Figure 67: Essential sharpening stones for periosteum and luxators

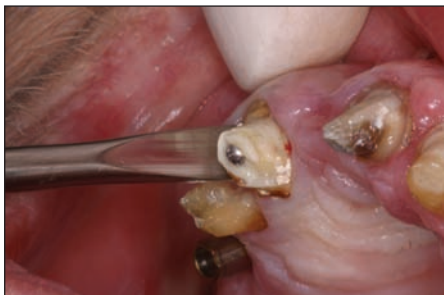

Figure 68: Luxator to loosen canine root. Note thumb placing pressure onto buccal to protect the bone

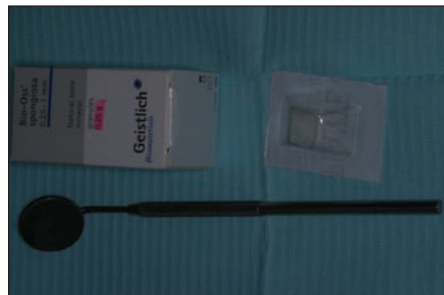

Figure 69: Bone graft material Bio-Oss & Collagen sponge and mirror handle to act as a packer

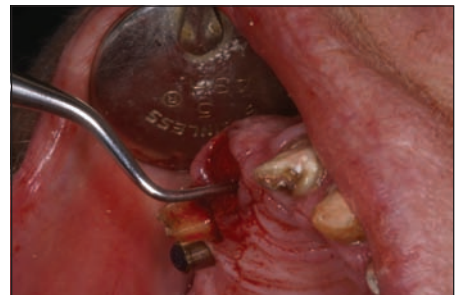

Figure 70: Debriding socket with curette

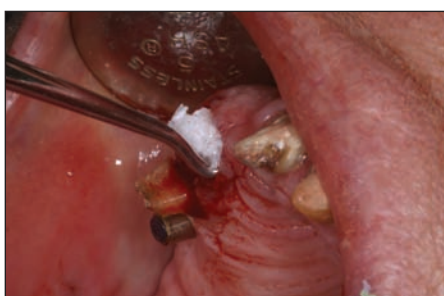

Figure 71: Packing moistened Bio-Oss (LA) used to hydrate Bio-Oss granules

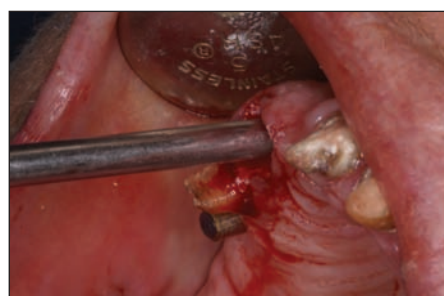

Figure 72: Packing firmly of graft material

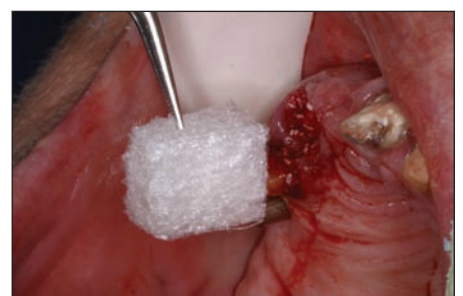

Figure 73: Collagen sponge to be applied to graft area

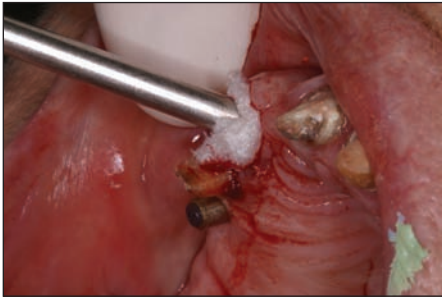

Figure 74: Packing of Collagen sponge

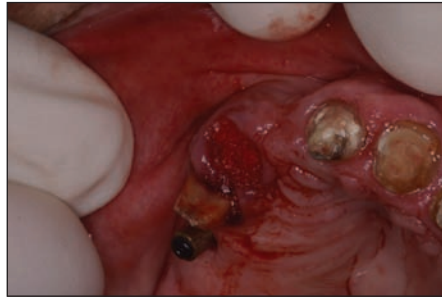

Figure 75: Packed socket showing well-filled but not over-packed socket with collagen sponge protecting the Bio-Oss graft

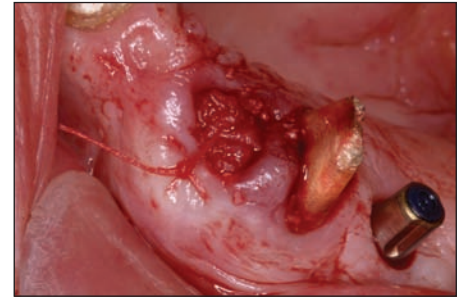


Figure 76: Socket secured with horizontal mattress suture to help secure graft

- Ridge splitting techniques: this allows for the division of shrunken ridges. The split ridge is then packed with a graft material or implants are placed simultaneously. This is less traumatic than block grafting as no donor site is involved. It does, however, require the ridge to have sufficient volume to be split predictably (Figures 62 and 63).

All of these techniques would now fall into the 'Major grafting and/or modifying the anatomy' category of implant treatment as defined by the working group for training standards in Implant Dentistry for General Dental Practitioners. All of these treatment solutions are predictable in experienced hands.

However, their training path now described by FGDP now makes the acquisition of the required experience more difficult and expensive in time and money to acquire. This may mean less of this potential treatment will be available.

But as a profession we should not endeavour to avoid these complex because:

- The patient will be happy
- The implant surgeon will be happy
- The technician will be happy.

How is this achieved? By preserving tissue and bone. The preservation of the volume and structure of the alveolus will make all aspects of dental treatment easier and, with the potential for better outcome, not only for dental implant treatment but also for more natural-looking bridges.

### How to preserve the alveolar structure

In order to preserve the natural ridge profile and architecture we must prevent the collapse of the bone volume. This has been shown to be possible by the packing the socket with an osteoconductive bone substitute<sup>8,10,11</sup>.

The presence of an osteoconductive graft material has been shown to maintain the volume of the alveolar structure<sup>8,10</sup>. Recently Nevins and a co-worker published a paper where the patients with the least favourable anterior maxillary sockets were treated with

a Bio-Oss graft (Geistlich Biomaterials). This was judged against comparable sockets left untouched. The comparison showed that Bio-Oss-treated sockets maintained similar architecture and volume after extraction.

The maintenance of alveolar ridge form would obviously help implant placement, but it can also help the placement of bridges, as the pontic shape and contour could be natural.

### Which bone substitute?

#### Why do we use bone augmentation material (BAM)?

1. To prevent the repair of large defects with 'scar-like' soft tissue rather than providing the circumstances for regeneration of the host bone
2. To provide an optimal environment for reconstruction using either dental implants or conventional prosthesis.
3. To prevent the shrinkage of the alveolus after the extraction of damaged natural teeth, thereby preventing aesthetic and anatomic changes to the jaws, bone and associated dental structures.

#### Ideal properties for socket preservation

- Easy to handle
- Safe
- Non immunogenic
- Readily available
- Stable over time to prevent shrinkage.

### Important definitions

- Osteoconduction – an implantable matrix that provides channels for bone growth at the interface. No osteogenic potential i.e. can not form new bone on its own.<sup>11</sup> (Callan, 2001)
- Osteo induction – an implantable matrix that provides natural stimulation of bone formation throughout the implantable material, not just at the interface.<sup>12</sup>

The above list of desirable qualities in a graft material should be applied to the following options:

- Autograft – autogenic bone is the patient's own bone. This is considered the 'gold standard' of bone augmentation material as it has unique features – the presence of viable bone forming cells (osteoblasts) – within its structure. It should pose no risk of antigenicity or infection if sterile protocol is observed. However, sufficient graft needs to be harvested from a second surgical site – the hip, mandible or fibula. Understandably, many patients are interested in an alternative to a second surgical site

- Bone allograft – non-vital bone taken from the same species (humans) and transplanted to another
- Demineralised freeze-dried bone allograft (DFDBA)
- Demineralised bone matrix (DBM)
- Irradiated bone.

These products are commercially available and no additional surgical sites are required, reducing the risks associated with additional procedures (e.g. pain, infection, swelling and so on). All have been shown to allow for repair of host bone defect by replacement of graft complex to viable host bone.

- Xenograft bone – osseous tissue harvested from another species and transferred to the patient's bone defect. Those most commonly used are:

- Bovine (cow) – Bio-Oss (Geistlich), Osteograft N (Dentsply Friadent)
- Equine (horse) – Biotek
- Coralline material – Bio-coral calcium carbonate – algipore (Dentsply Friadent). Most commonly presented as an organic material with bone-like structure allowing host bone to grow over and through it creating a 'scaffold' for new bone
- Alloplastic material – synthetic chemically derived material – hydroxapatite. It is synthetically manufactured, can be resorbable or non-resorbable. The resorbable type can be used as osteoconductive material. The non-resorbable type must not be used in combination with bone augmentation, but has been used to sup-

# Clinical debate

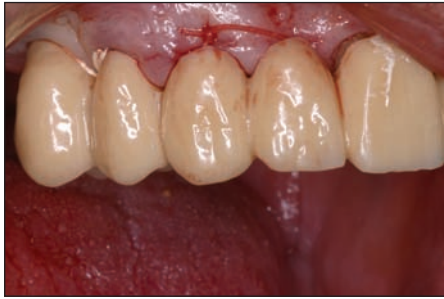

Figure 77: Provisional bridge secured into position

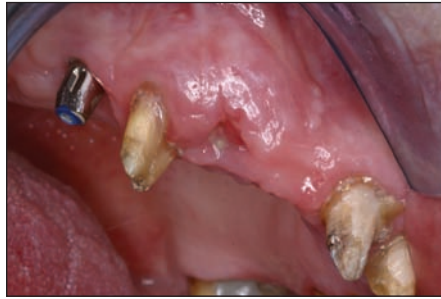

Figure 78: Ridge contour four months later

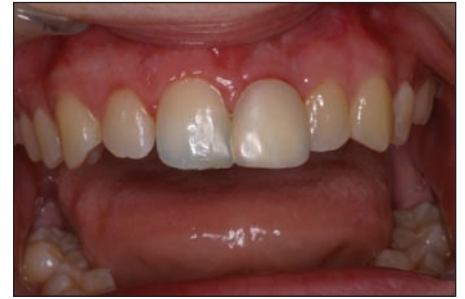

Figure 79: Seventeen years after extraction and socket preservation using Bio-Oss with adhesive bridge as a provisional

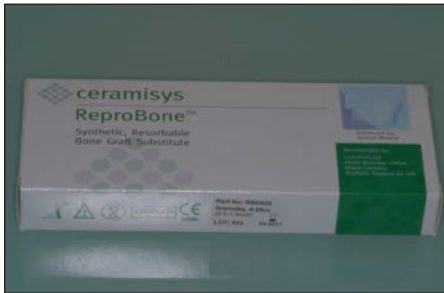


Figure 80: Reprobone synthetic allograft



Figure 81: 1cm cube of collagen

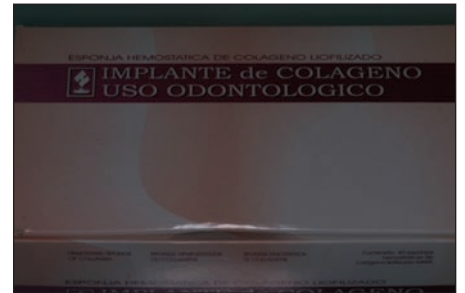

Figure 82: Collagen sponges



Figure 83: Straumann bone ceramic synthetic bone allograft

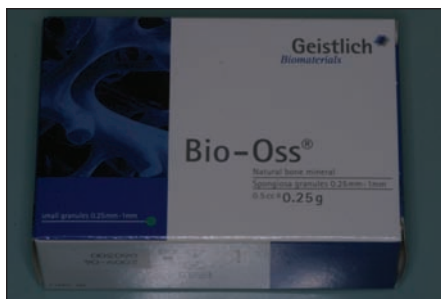


Figure 84: Bio-Oss 0.5 G package xenograft

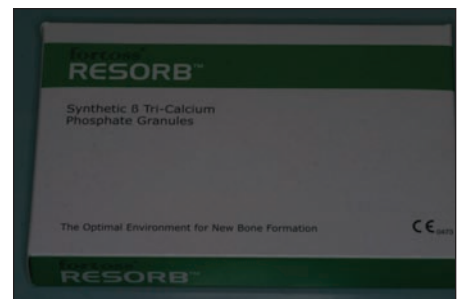


Figure 85: Resorb synthetic allograft beta tricalcium phosphate

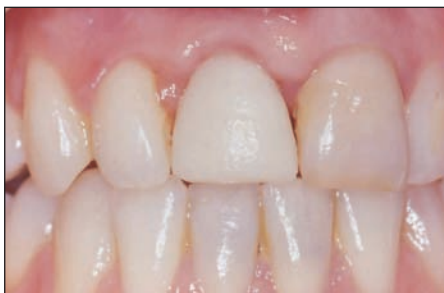

Figure 86: Temporary crown in situ

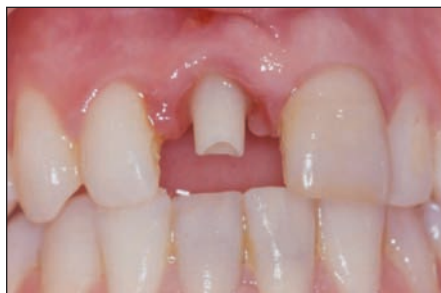

Figure 87: Ceramic abutment in situ ready to have the abutment level impression



Figure 88: Procera coping to be used as impression coping

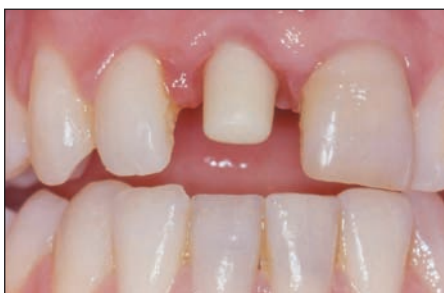

Figure 89: Coping fitted over abutment ready for impression technique

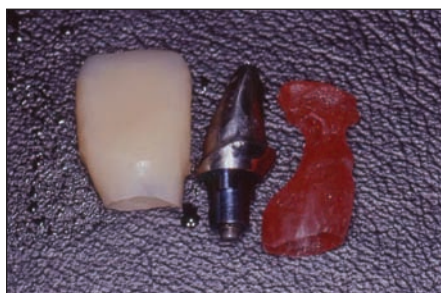

Figure 90: Components necessary for abutment level impression of a customised impression

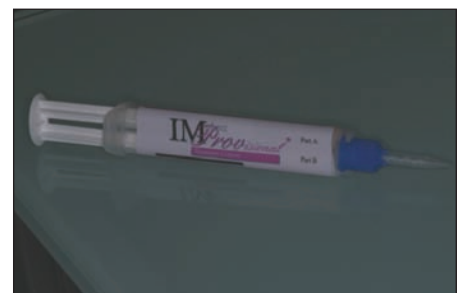


Figure 91: Improv implant-specific cement

port soft tissue contour.

Ceramics include:

- Tricalcium phosphate alpha and beta
- Bioglasses
- Calcium sulphates.
- Combined HA<sub>2</sub>TCP and tricalcium phosphates, for example Reprobone and Straumann bone ceramic.

## How can this be handled in general practice?

**Stage one:** atraumatic extraction – every effort should be made to preserve all of the remaining alveolar bone (Figure 68).

The use of sharp luxators (Figures 65, 66 and 67), Periostomes (Figure 64) and the division of multi-rooted teeth and the separate annotation of individual roots will ensure that as much bone as possible is maintained.

**Stage two:** the socket should be carefully cleaned. This is ideally performed using curettes such as the Lucas curettes (Figure 70). However, rotary instruments can be used to remove the remnants of soft tissue and periodontal ligament fibres.

**Stage three:** the socket can now be packed with a grafting material (Figures 71 and 72).

The socket should be packed with the material to allow enough space for the collagen sponge to be installed. This will mean leaving 2-3mm between the top of the graft and the soft tissue margins. The packing of the graft is helped by moistening the particular material (Figure 71), usually with local anaesthetic. Once packed down the collagen sponge is pushed into position and secured with a horizontal mattress suture (Figures 73 to 76) or a 'figure of 8' suture over the collagen. The socket now needs to be provisionalised and the graft left to mature for at least four months (Figure 77).

'Because the loss of a tooth allows alveolar bone to resorb, because of loss of function, bone grafting at the time of tooth removal provides bone quality and quantity to be available for future implant treatment. It is recommended that all extraction sites be grafted even when implants are not anticipated. See Figure 79, which shows a site grafted seven years previously with the same technique, as the patient was then too young for an implant-supported restoration.

'The preservation of alveolus will enhance support of a removable prosthesis and better cosmetic results for conventional dentistry.'<sup>11</sup>

The maintenance of the alveolus will also simplify any potential future implants as vol-

ume of bone will be more optimal, allowing for:

1. Longer implants
2. Wider implants
3. Natural aesthetics and emergence profile
4. Ideal position and number of implants
5. Implants at ideal angle, simplifying placement and restorative procedure
6. Greater implant predictability due to simplified implant placement procedures
7. Simpler placement procedures allowing:
  - i) A greater number of practitioners to be able to offer this treatment predictability
  - ii) Reduced morbidity to the patient through shorter more straightforward surgery
  - iii) Lower financial costs for implant placement.

The early prevention of bone loss and alveolar resorption prevents the need for complex augmentation procedures and should, as a routine, be recommended and documented to allow the practitioner to demonstrate, in the event of a complaint, that tissue preservation was recommended (Figures 59 to 63).

## Conclusion

The number of patients who are going to undergo treatment involving implants is likely to increase substantially in the UK.

Dentists in general practice need to be more aware of the implant option and the need to offer this to patients, so that proper informed consent for treatment can be obtained.

The expected rise in the number of implants placed and implant-related treatments such as bone grafting will require dentists to work together with implantologists more closely than they have in the past.

Many opportunities exist for general dentists to develop skills in implant-based treatments and to incorporate these into their patients' treatment without necessitating them learning implant surgical skills.

It is essential that training pathways, including mentoring, are developed in accordance with evolving guidance from the FGDP and General Dental Council.

## Acknowledgements

- Joy Elias Codicote Dental Laboratories: cdlelias@aol.com.
- Jerome at Griffen Dental Laboratories, Byfleet.
- Thomas Hardt at Reubeling Dental Laboratory, BremenHaven, Germany for excellent laboratory support: info@ruebeling.de.
- Mandy Jeffrey, Carole Holland and Wendy Leach for secretarial and IT help.

## References

1. Christensen GJ (2000) Clinical Research Associates, Provo Utah 84604, USA. Implants and general practitioners. *J Amer Dent Assoc* **131**: 359-361
2. Levi A et al (2003) Patient self-reported satisfaction with maxillary anterior dental implant treatment. *Int J Oral Maxillofac Implants* **18**: 113-120
3. Tan K et al (2004) A systematic review of the survival and complication rates of fixed partial dentures (FPDs) after an observation period of at least 5 years. III Conventional FPDs. *Clin Oral Impl Res* **15**: 654-666
4. Priest G (1999) Simple-tooth implants and their role in preserving remaining teeth: A 10-year survival study. *Int J Oral Maxillofac* **14**(2): 181-188
5. Brägger U, Krenander P and L and N (2005) Economic aspects of single-tooth replacement. *Clin Oral Impl Res* **16**: 335-341
6. Esposito M et al (1998) Biological factors contributing to failures of osseointegrated oral implants.(I). Success criteria an epidemiology. *Eur J Oral Sci* **106**: 527-551
7. Gibson R and Barclay C (2006) Dental implantology education: A survey of opinion and experience of 10 general practitioners. *British Dental Journal* **201**: 367-370
8. Lekovic V, Camargo PM, Kokkevold PR et al (1997) Bone regenerative approach to alveolar ridge maintenance following extraction. A report of 10 cases. *J Periodontol* **68**: 563-570
9. Tallgren A (1972) The continuing reduction of the residual ridges in complete denture wearers: a mixed longitudinal study covering 25 years. *J Prosthet Dent* **27**: 120
10. Nevins M et al (2006) A study of the fate of the buccal wall of extraction sockets of teeth with prominent roots. *Int J Perio Rest Dent* **26**: 19-29
11. Callan D (2001) *Hard Tissue Grafting for Conventional and Implant Reconstruction*. Chapt 6a; *Dental Implants: The Art and Science*. WB Saunders Company
12. Urist MR et al (1967) The bone induction principle. *Clin Orthop* **53**: 243

## Table of bone substitutes

This table is an overview of available products (it is not intended to name all those commercially available)

Class of material	Name	Osteoconductive	Osteoinductive	Socket preservation
<b>Bone allograft</b>				
1)	Demineralised bone matrix particles (accredited tissue banks)	✓	✓	✓
2)	Mineralised cortical particles (accredited tissue banks)	✓	✓	✓
3)	Dynagraft II demineralised freeze-dried bone allograft.	✓	✓	✓
4)	Putty and gel (Innova Dental Implants)	✓	✓	✓
5)	Grafton DBM putty, gel, plugs etc. (Osteotech)	✓	✓	✓
<b>Alloplastic</b>				
Hydroxyapatite (resorbable) with tricalcium phosphate as a combined porous material	Reprobone (General Medical)	✓	0	✓
	Bone Ceramic (Straumann)	✓	0	✓
<b>Coraline material</b>				
Calcium carbonite	Biocoral (Biocoral Inc.)	✓	0	✓
Hydroxyapatite (resorbable)	Aligipore (Dentsply Friadent)	✓	0	✓
Tricalcium phosphates	Fortoss, Resorb (General Medical)	✓	0	✓
	Fortoss Vital (General Medical)	✓	0	✓
	Cerasort (Cursan)	✓	0	✓
<b>Bioglasses</b>				
	Perioglass (General Medical)	✓	0	✓
	Biogran (3i) Dental Implant	✓	0	✓
<b>Polymers</b>				
	HTR polymer (calcium layer polymer of polymethylmethacrylate & hydroxyethyl-methacrylate (non-resorbable)(Kerr Dental)	✓	0	✓
<b>Xenograft bone</b>				
	Bio-Oss (Geistlich)	✓	0	✓
	Osteograft N (Dentsply Friadent)	✓	0	✓
	Peppen 15	✓	0	✓

13. Pjetursson B, et al (2004) A systematic review of the survival and complication rates of fixed partial dentures (FPDs) after an observation period of at least five years. IV Cantilever or extension FPDs. *Clin Oral Impl Res* 15: 625-

642

14. Pjetursson B et al (2005) Patients' satisfaction following implant therapy. A 10-year prospective cohort study. *Clin Oral Impl Res*

16(5): 185-193

15. Millenium Research Group: US market for dental implants 2003, Global Dental Series, Toronto, Ontario USD1 03; Jan 2003

16. Stillman N, Douglass CW (1993) Developing markets for dental implants. *J Am Dent Assoc* **124**: 51-56
17. Nobel Biocare 2005
18. Misch C (2005) *Dental Implant Prosthetics*. Mosby Inc
19. Hellmich N (2003) Extra weight shaves years off lives. *USA Today* Jan 7 A.01
20. *Training Standards in Implant dentistry for General Practitioners*. Working Group for training standards in Implant Dentistry for General Dental Practitioners, December 2005 (www.fgdp.org.uk)
21. Esposito M et al (1998) Biological factors contributing to failures of osseointegrated oral implants (II). Ethioopathogenesis. *Eur J Oral Sci* **106**: 721-764
22. Jacobs R, Van Steenberghe (1991) Comparative evaluation of oral tactile function by means of teeth and/or implant-supported prostheses. *Clin Oral Impl Res* **2**: 75-80
23. Hansard (2002) Since 1997-98 more dentists have joined than left. The number of GDS dentists has increased from 16,387 at March 1997 to 18,254 in March 2002, an increase of 1,867. Dentists are able to vary the amount of work they do in the GDS. 19 September 2002
24. The scarcity of skills in the UK is associated with high prices. Cost quoted in the UK are typically £2,000 per implant upward compared with about £1,000 or less in some other European countries. Costs are widely expected to fall with the development of supporting technologies. But because of the scarcity of implantologists in the UK falling costs can be expected to increase the difference between the high costs in the UK as compared with the low cost in other countries.
25. There are many things the NHS can do to raise knowledge and skills of implantology among its own staff. But there is no obvious way of bringing a whole generation of dentists in the UK up to standard that seems common in other European countries. Such developments go beyond the scope of this submission and the role of the Health Committee.
26. Thomas R (2005) Open University. December. Prepared 18 January 2006
27. Muhlemann HR, Savdirl S, Rakeitshak KH (1965) Tooth Mobility: its cause and significance. *J Periodontal* **36**: 148-153
28. Sekine H, Komiyama Y (1986) Mobility characteristics and tactile sensitivity of osseointegrated fixture supporting systems. In van Steenberghe D, editor: *Tissue integration in oral maxillofacial reconstruction*, Amsterdam. Elsevier.
29. Williamson EH, Lundquist DO (1983) Anterior guidance: its effect on electromyographic activity of the temporal and masseter muscles. *J Prosthet Dent* **49**: 816-823
30. Weinberg LA, Kruger G (1995) A comparison of implant/prosthesis loading for clinical variables. *Int J Prosthodont* **8**: 421-433
31. Lang N, et al (2004) A systematic review of the survival and complication rates of fixed partial dentures (FPDs) after an observation period of at least five years. II Combined tooth-Implant-supported FPDs. *Clin Oral Impl Res* **15**: 643-653
32. Berglund T, Lindhe J (1997) Healing around implants placed in bone defects treated with Bio-Oss. An experimental study in the dog. *Clin Oral Implants Res* **8(2)**: 117
33. Valentini P et al (1998) Histological evaluation of Bio-Oss in a two-stage sinus floor elevation and implantation procedure. A human case report. *Clin Oral Implants Res* **9(1)**: 59
34. Mellonig JT, Bowers GM, Baily R (1981) Comparison of bone graft materials. Part I New bone formation with autografts and allografts determined by Strontium-85. *J Periodontal* **52**: 291
35. Mellonig JT, Bowers GM, Cotton W (1981) Comparison of bone graft materials. Part 2. New bone formation with autografts and allografts: A histological evaluation. *J Periodontal* **52**: 297
36. Tallgren A (1972) The continuing reduction of the alveolar ridges in complete denture wearers: a mixed longitudinal study covering 25 years. *J Prosthet Dent* **27**: 120
37. Atwood DA (1962) Some clinical factors related to the rate of resorption of residual ridges. *J Prosthet Dent* **12**: 441

To be sure of reading the continuation of this article, please subscribe to *Implant Practice US*.

This second part of this article will be printed in the next issue of *Implant Practice US*.